

## Recanalisation of urethral strictures with new-generation temporary covered biocompatible metal endoprostheses

Ž. Marković<sup>1</sup>, B. Marković<sup>2</sup>, C. Tulić<sup>2</sup>, J. Hadži-Djokić<sup>2</sup>,  
V. Stojanović<sup>1</sup>, Dj. Šaranović<sup>1</sup>, D. Mašulović<sup>1</sup>, S. Miljković<sup>3</sup>

<sup>1</sup> Institute of Radiology, Clinical Centre of Serbia, Belgrade

<sup>2</sup> Institute of Urology and Nephrology, Clinical Centre of Serbia, Belgrade

<sup>3</sup> Clinical Centre, Niš

### Abstract

**Treatment of strictures of the male urethra is a clinical issue, for which minimally invasive interventional uroradiology methods are increasingly being used. Despite that this method has been used for the past 20 years, the therapeutic has yet to be defined. The results of the use of temporary self-expandable covered nitinol Allium urethral stents are presented. These stents have been used in our institution since October 2003. Over the course of 3 years, 40 men, mean age 54 years, with urethral strictures that had previously been treated with urological methods have been treated with these stents. In 4 cases, the stent was placed following an optical urethrotomy. The most frequent etiologies for the strictures were post-traumatic (55%), post-inflammatory (32%), iatrogenic (10%) and the rest of unknown etiology. In all cases, the stent was removed 12-14 months after insertion. The results were evaluated using uroflowmetry and urethrocytography. Permanent recanalisation without voiding problems was observed in 85% of cases. In 12.5% of cases a stricture developed at the distal end of the stent**

Key words: urethra, stricture, covered stents, recanalisation

### INTRODUCTION

The pathophysiological sequence of changes occurring following an injury of the male urethra starts with submucosal changes, constriction and cellular disintegration<sup>1</sup>. This is followed by processes of cellular destruction, increased phagocytosis, neutrophilic inhibition and fibroblastic activation. The damaged segment of the urethra transforms to a fibrotic, avascular scar, which with time undergoes cicatrization and has the histopathological appearance of a scar. The rate at which the urethral stricture develops depends on the site, aetiology and severity of the lesion and on the age of the patient. Contemporary urology makes use of a number of surgical methods in the treatment of urethral strictures. Endourological methods predominate, while open surgery consisting of excision and reanastomosis or of buccal mucosa patching which is used as a last resort. Repeated dilation using various types of bougies is the most used therapeutic option, which represents practically the simplest possibility for maintaining urethral patency in the event of recurrence. The most common consequence dilation of the urethra is its transformation to a chronic state and shortening of the intervals between dilatations.

The use of recanalisation using high pressure balloon catheters (20-22 atm), as well as the insertion of various generations of metal stents, during the past 20 years, has to a significant degree changed the fundamental therapeutic concepts of treating urethral strictures<sup>1</sup>. The first authoritative therapeutic algorithm was defined in 1996 (1<sup>st</sup> International Symposium on Urological Stents, Jerusalem - Israel) (Figure 1). The results of treatment with metal stents during the following 6 years demonstrated the significance of this new method, but also its weaknesses, above all due to secondary obstructions caused by reactive tissue proliferation. It also demonstrated that the use of temporary stents was a better choice than the use of permanent stents<sup>1</sup>. The use of the covered metal

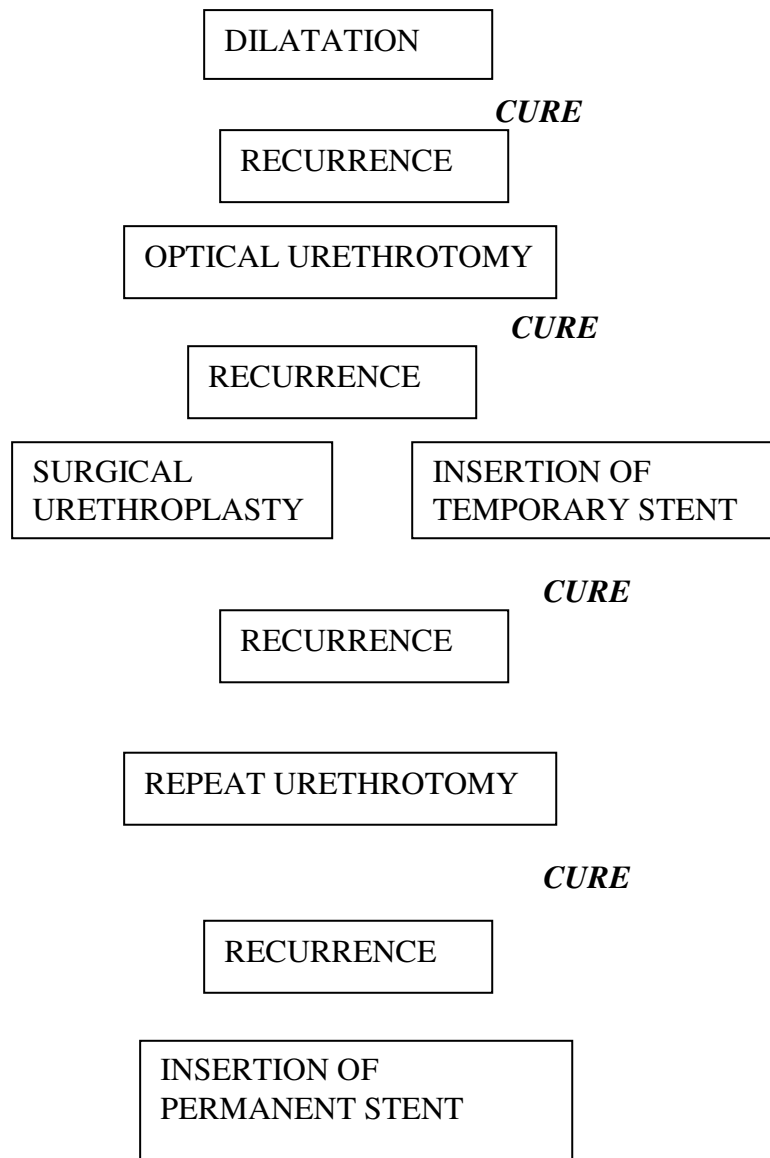
urethral stents, which were used for the first time in this study, has provided new possibilities and new experience.

## *MATERIALS AND METHODS*

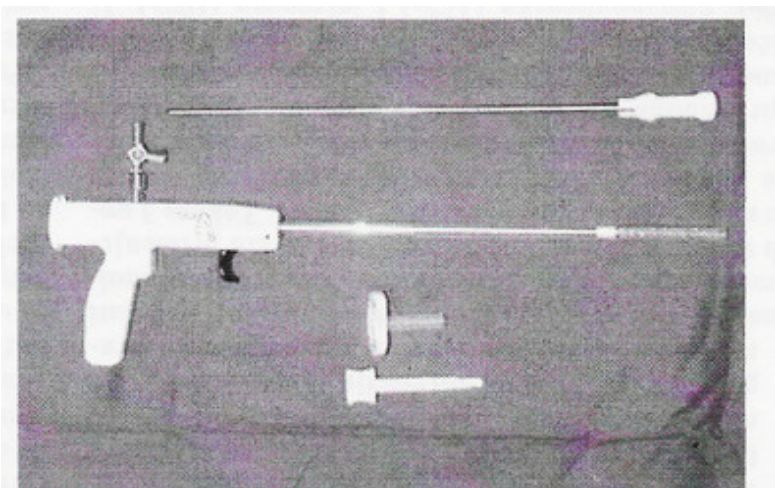
From October 2003 to December 2005, insertion of a temporary, covered Allium urethral stent was performed in 40 patients with recurrent stricture of the bulbar urethra. Patients were aged 28-73 years (mean age 56). The etiology of the structure was as follows: 22 post-traumatic, 13 post-inflammatory, 4 iatrogenic, 1 unknown. All patients had previously been treated with various palliative or surgical methods for an average period of 2 years. Insertion of Allium bulbar urethral stents was part of an international scientific research project, approved by the Ethics Committee of the Clinical Centre of Serbia and conducted in accordance with all European regulations concerning scientific research in human. The stent used were evaluated during one-year in the laboratory and then studied in an animal model. Treatment was performed on an outpatient basis in all cases. Pre-insertion evaluation included urethrocystography (UCG), post-micturition cystography (PMCG) and uroflowmetry. It also included laboratory urine tests, because urinary tract infection was a contraindication for stent insertion.

Antibiotic prophylaxis was started two days before stent insertion. The procedure was done under local anaesthesia, systemic analgesia and sedation was added when necessary.

The procedure was started with a UCG to visualise the stricture. This was followed by insertion of a guide-wire and balloon to 10 mm, a procedure well known in interventional urology of the male urethra<sup>1</sup>. Allium urethral stents are formed from a biocompatible metal alloy, nitinol, and coated with a novel copolymer. (Figs. 2 and 3). They come mounted on a 24 Fr delivery tool. The stents are self-expandable, and intended for temporary use. The stent is composed of two segments: the main body of the stent which comes in variable lengths and the short sphincteric segment which looks like a half-open umbrella. The sphincteric segment is the proximal segment and is soft for not disturbing the contraction of the external urethral sphincter (EUS). This construction of the sphincteric segment (Figs. 4 and 5) significantly decreases the possibility of a lesion of the EUS, which is a relatively frequent occurrence with earlier generations of urethral stents (Ultraflex, Memokath, Urolume and others)<sup>1</sup>. The delivery tool comes in two forms: rigid and flexible (Figs. 2 and 3). Both systems can be used under fluoroscopic (Fig. 6). The rigid delivery tool can be used for endoscopic insertion of the stent. After balloon dilation the stent is inserted over a metal guide wire or a 5 Fr catheter, which serves as a guide. Positioning of the stent is done under fluoroscopic control in such a way that the sphincteric end of the stent is just below the sphincter and the downstream end of the stent covers at least 5mm distally the healthy urethra. The anterior ring of the delivery tool is pulled manually for releasing the stent. The full lumen of the stent is attained almost immediately. (Figs. 7, 8 and 9) Following withdrawal of the delivery tool, the guide also was removed. Antibiotic treatment was continued for 5 additional days.

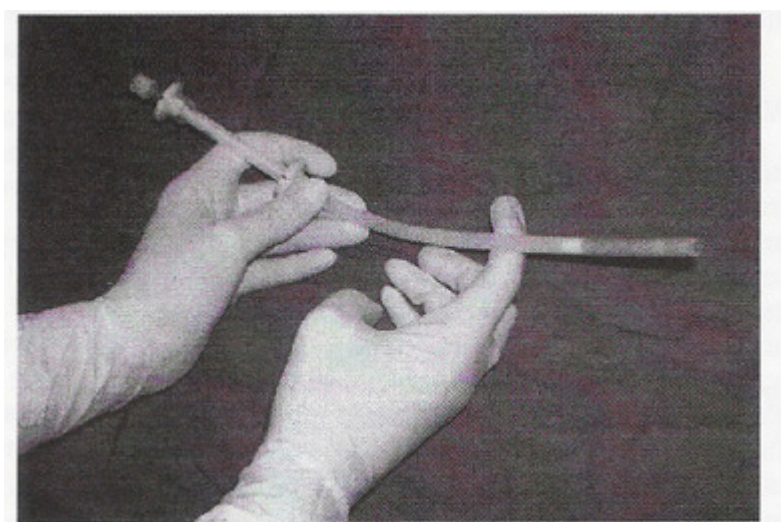


**FIGURE 1.**  
Therapeutic algorithm for the treatment of urethral strictures.



**FIGURE 2**

Temporary self-expanding covered Allium Bulbar Urethral Stent – Rigid delivery tool for endoscopic or fluoroscopic insertion.



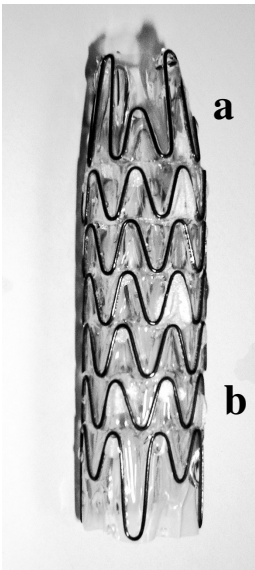
**FIGURE 3**

Allium Bulbar urethral stent mounted on a flexible delivery tool for fluoroscopic insertion.

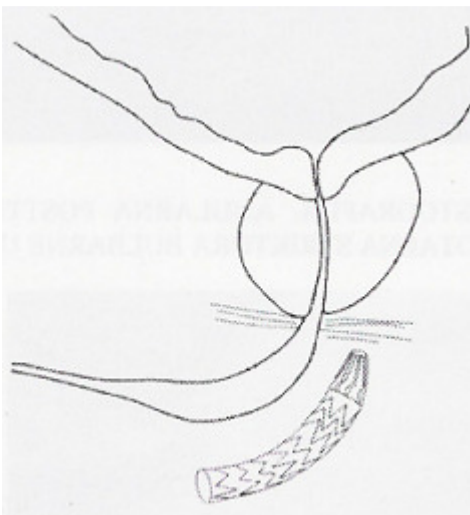
## **RESULTS**

Evaluation of the results was done according the protocol. The immediate result showing recanalisation of the stricture and the position of the stent was confirmed by follow-up urethrocystography. In three cases (7.5%), the stent was malpositioned during insertion, due to which it was repositioned in two of these cases they were repositioned using a balloon catheter, which was placed into the lumen and outward pulling, while in the third case the stent was removed and a new one inserted instead. In all cases, primary UCG revealed complete recanalisation of the urethral stricture and a good impression was obtained concerning the force and duration of the first micturition following insertion. On the day after the insertion, the patients were interviewed by telephone. None had problems with irritation. In 7 cases (17.5%), minimal haematuria was present, which resolved spontaneously during the next two days. A uroflowmetry follow-up examination was performed after 30 days and UCG was performed at 3 and 6 months after insertion. All findings showed good therapeutic results. Complications included outward migration of the stent by 1-2 cm in two cases. In both cases, the “stent through stent” technique was performed, with the stents

overlapping each other by approximately 1 cm. At 12-13 months after insertion, the stents were removed easily using an endoscopic forceps. In 5 cases (12.5%), follow-up UCG following removal of the stent showed the presence of a significantly obstructing tissue proliferation at the site of contact between the downstream end of the stent and the urethral wall.

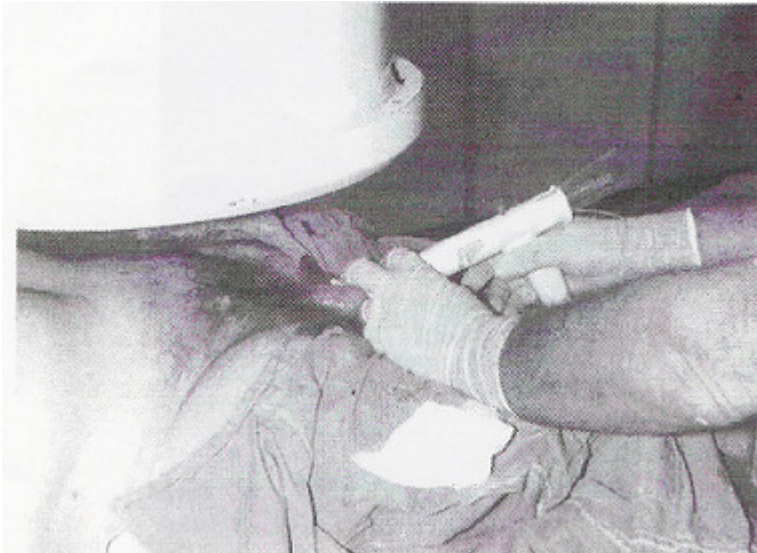


**FIGURE 4.**  
Expanded Allium Bulbar Urethral Stent.  
a- Sphincteric segment  
b- Main body

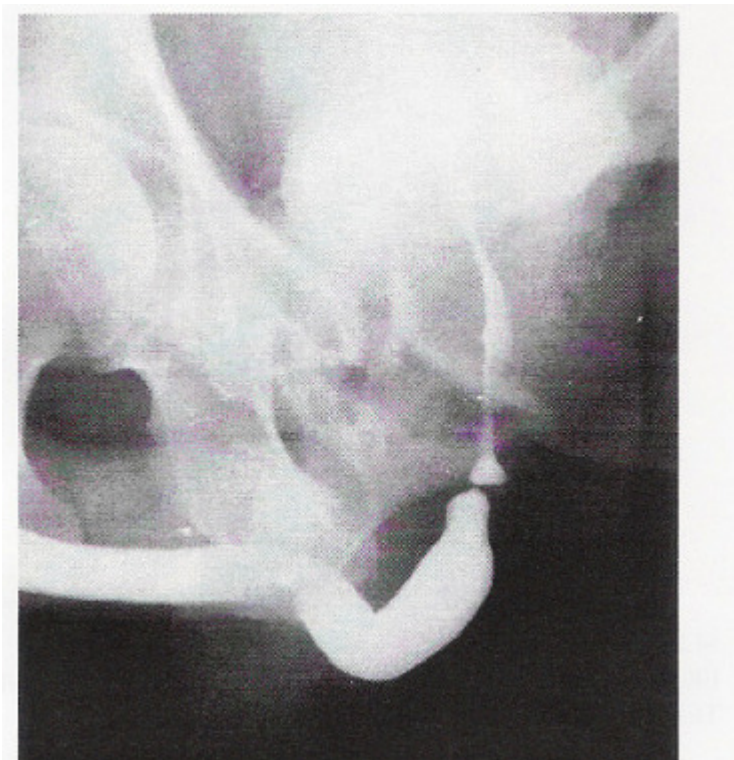


**FIGURE 5**  
Position of the sphincteric segment of the stent  
in relation to the external urethral sphincter.

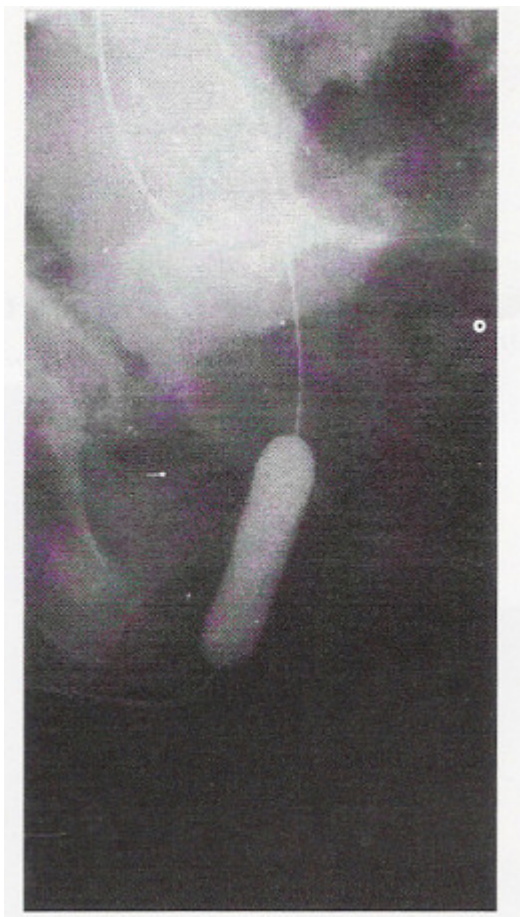



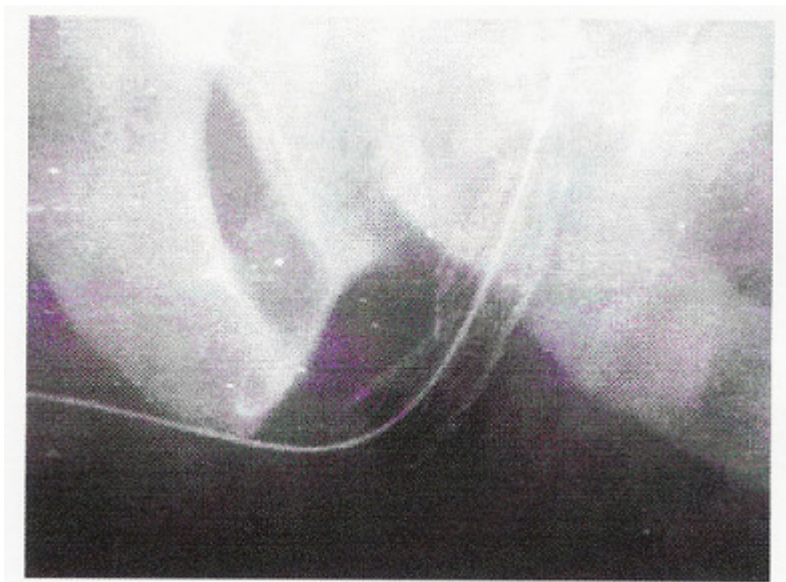
**FIGURE 6**  
Stent insertion under fluoroscopic control



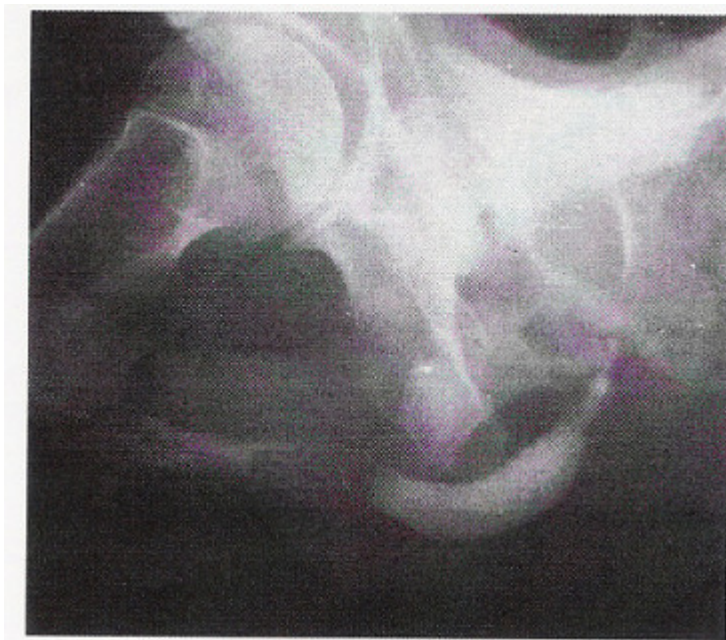
**FIGURE 7**  
Urethrocystography: annular short traumatic bulbar stricture very near the external sphincter.



**FIGURE 8**  
Balloon dilation of the stricture



**FIGURE 9**  
Allium Bulbar Urethral Stent after its release over a metal  
guide-wire



**FIGURE 10**  
Urethrocytography after stent insertion

### *DISCUSSION*

Recanalisation of strictures of the male urethra using the Allium covered stents is a new method for the treatment of this disease. Allium stents are covered with a novel thin and firm co-polymer cover which prevents the growth of reactive tissue into the lumen of the stent. The development of a secondary obstructive tissue proliferation is a known complication occurring in more than 50% of cases with the earlier-generation stents such as Ultraflex etc. We have seen such a complication in only 12.5% of patients in whom we inserted the Allium Bulbar Urethral Stent. With respect to the duration of use, Allium stents belong to the temporary category, which undoubtedly favours their use. During the course of one year of indwelling, a large calibre scar develops around the Allium stent. The development of secondary strictures at the downstream margin of the stents may be explained by reactive tissue proliferation as the result of the pressure of the metal covering of this part of the stent to the healthy urethra. We did not observe development of secondary strictures in the sphincteric area since this end of the Allium stent is atraumatic.

### *CONCLUSION*

Covered stents have significant advantages over earlier-generation bare metal urethral stents. Their clinical use represents a therapeutic advance in the management of strictures of the male urethra. Their most important advantage is the significant reduction of reactive tissue growth and the recurrence of the stricture. Currently, bare metal urethral stents are used as a treatment of last resort in recurrent strictures of the male urethra. The definitive place of covered metal stents in the therapeutic algorithm will be defined by their wider use in various etiological groups.

### *BIBLIOGRAPHY*

1. Yachia D. (Ed). Metal Stents in Urinary System, ISIS medical media, Oxford, 1999
2. Markovic Z. Nevskularna interventna urologija, Medicinski fakultet u Beogradu, 1996

[Non-vascular interventional urology, Medical Faculty, Belgrade]



3. Hadži-Djokić J (Ed.) Metalni stentovi u urologiji, BIGZ Beograd, 1999

[Metal stents in urology]

4. Evans P A M, Nisbet A P, Saxton H M. Antegrade ureteric stents in malignant disease. *J Intervent Radiol* 1988; 3(1): 9-13

5. Gunther R W, Alken P. Percutaneous nephropylotomy: applications, technique and critical evaluation. In: Wilkins R A, Viamonte M Jr (eds) *Interventional radiology*. Oxford: Blackwell Scientific Publications, 1982: 333-355

6. Flueckiger F, Lammer J, Klein G E et al. Malignant ureteral obstruction: preliminary results of treatment with metallic self-expendable stents. *Radiology* 1993; 186: 169-173

7. Goodwin W E, Casey W C, Woolf W. Percutaneous trocar (needle) nephrostomy in hydronephrosis. *JAMA* 1955; 157: 891-894

8. Tadavarthy S M, Coleman C C, Hunter D W et al. Percutaneous urologic techniques. In: Casta(eda-Zuiga WR, Tadavarthy SM (eds) *Interventional radiology*. Baltimore: Williams and Wilkins, 1988: 423-621

9. Pollak J S, Rosenblatt M M, Egglin T K et al. Treatment of ureteral obstructions with the Wallstent endoprosthesis: Preliminary results. *JVIR* 1995; 6(3): 417-425

10. Fritzsche P J. Antegrade and retrograde ureteral stenting. In: Lang E K (ed) *Percutaneous and interventional urology and radiology*. Heidelberg: Springer-Verlag, 1986: 91-111

11. Docimo S G, Dewolf W C. High failure rate of indwelling ureteral stents in patients with extrinsic obstruction: experience at 2 institutions. *J Urol* 1989; 142: 277-279

12. Gort H B W, Mali W P, van Wacs P F, Kloet A G. Metallic self-expandable stenting of a ureteroileal stricture. *AJR* 1990; 155: 422-423

13. Lugmayr H, Pauer W. Self-expanding metal stent for palliative treatment of malignant ureteral obstruction. *AJR* 1992; 159: 1091-1094

14. Reinberg Y, Ferral H, Gonzalez R et al. Intraureteral metallic self-expanding endoprosthesis (Wallstent) in the treatment of difficult ureteral strictures. *J Urol* 1994; 151: 1619-1622

15. Lugmayr H, Pauer W. Selbstexpandierende metallstents bei malignen ureterstenosen. *Dtsch Med Wochenschr* 1991; 116: 573-576

[Self-expanding metal stents in malignant ureteral stenoses]

16. vanSonnenberg E, D'Agostino H B, O'Laoide R et al. Malignant ureteral obstruction: treatment with metal stents - technique, results and observations with percutaneous intraluminal US. *Radiology* 1994; 191: 765-768
17. Lezin M A, Stoller M L. Surgical ureteral injuries. *Urology* 1991; 38: 498-506
18. Turner W H, Cranston D W, Davies A H et al. Double-J stents in the treatment of gynaecological injury to the ureter. *J R Soc Med* 1990; 83:623-624
19. Andriole G L, Bettman M A, Garnick M B, Richie J B. Indwelling double-J ureteral stents for temporary and permanent urinary drainage: experience with 87 patients. *J Urol* 1984; 131: 239-241
20. Chang R, Marshall F F, Mitchell S S. Percutaneous management of benign ureteral strictures and fistulas. *J Urol* 1987; 137: 1126-1131
21. Pingoud E G, Bagley D H, Zeman R K et al. Percutaneous antegrade bilateral dilation and stent placement for internal drainage. *Radiology* 1980; 134: 780
22. Harshman M W, Pollack H M, Banner M P, Wein A J. Conservative management of ureteral obstruction secondary to suture entrapment. *J Urol* 1982; 127: 121-123
23. Goodwin W E, Caset W C, Woolf W. Percutaneous trochar (needle) nephrostomy in hydronephrosis. *JAMA* 1955; 157: 891-894
24. Beckman C F, Roth R A, Bihle W III. Dilatation of benign ureteral strictures. *Radiology* 1989; 172: 437-441
25. Conlin M J, Bagley D H. Incisional treatment of ureteral strictures. Smith AD (ed). *Smith's Textbook of Endourology* 1996: 497-505
26. Eshghi M, Franco I, Hernandez-Graviav J, Schwalb D. Cold knife endoureterotomy of 79 strictures: technique and 5 -years follow-up. *J Urol* 1992; 147(part 2): 471A (abstr 1036)
27. Cussenot O, Bassi S, Desgrandchamps F et al. Outcomes of non-selfexpandable metal prostheses in strictured human ureter: suggestions for future developments. *J Endourol* 1993; 7: 205-209
28. McKay T C, Albala D M, Gehrin B E, Casttell M. Laparoscopic ureteral reanastomosis using fibrin glue. *J Urol* 1994; 152: 1637-1640
29. Chandhoke P S, Clayman R V, Stone A M et al. Endopyelotomy and endoureterotomy with the Acucise ureteral cutting balloon device: preliminary experience. *J Endourol* 1993; 7: 45-51
30. Reinberg Y, Ferral H, Gon.,ales R et al. Intraureteral metallic selfexpanding endoprosthesis (Wallstent) in the treatment of difficult ureteral strictures. *J Urol* 1994; 151: 1619-1622